

GATOR DOCPERIODICAL

The UF Internal Medicine Newsletter

SURGE EDITOR

None of us anticipated this summer to play out as it has...
 Although Shands busier than it's ever been, it's always worthwhile to celebrate our July interns/resident of the month:

Claudia Hernandez



Where are you from? *Southwest Florida*
As a child, what did you want to be when you grew up? *Professional Slime Time slimer on Nickelodeon.*
What's your favorite dessert?
Flan
What's your favorite way to spend your day off?
Spending too much time and money on a garden because just buying the tomato for a fraction of the cost is not enough.

Lauran Zeineddine



Where are you from? *Atlanta, GA*
As a child, what did you want to be when you grew up? *POTUS*
What's your favorite dessert?
High Five Candy Bar ice cream from Jeni's
What's your favorite way to spend your day off? *Walking rounds.*



Catherine Kim

Where are you from? *Atlanta, Georgia*
As a child, what did you want to be when you grew up? *A ballerina and an astronaut*
What's your favorite dessert?
Blackberry oreo cheesecake
What's your favorite way to spend your day off?
Grocery shopping at Trader Joe's and then taste testing all their new snacks and frozen foods

QUESTION? OF THE MONTH:

An 85-year-old woman is evaluated for left knee pain of moderate intensity that occurs with ambulation and at night. Acetaminophen provides no relief. History is significant for coronary artery disease, hypertension, and stage 3 chronic kidney disease. Medications are aspirin, lisinopril, metoprolol, and vitamin D.

On physical examination, blood pressure is 152/88 mm Hg; other vital signs are normal. The left knee demonstrates crepitus and decreased passive range of motion; a small effusion is present, and there is no warmth or tenderness. Joint aspiration of the left knee shows a leukocyte count of 1100/μL (1.1 × 10⁹/L).

Which of the following is the most appropriate treatment for long-term symptom control?

- A: Intra-articular glucocorticoid injections
- B: Low-dose prednisone
- C: Naproxen
- D: Oxycodone
- E: Topical diclofenac

Answer E: Topical diclofenac

RESIDENTS OUT AND ABOUT!

COVID's making rounds and so are we:



Gold Med with some beautifully crafted birthday apple pie



These PGY-3's looking absolutely fabulous in their seafoam green scrub attire



Ellery Altshuler campaigning for the office of Surgeon General



Dr. Smoot showing off some wild heart murmurs to this lucky group of students

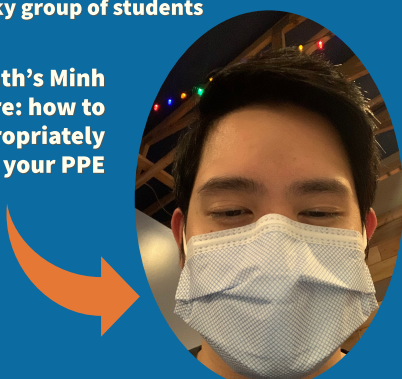


Dr. Hahn bringing baked goods and smiles every where she goes!



Giving the unofficial fourth gold medicine intern some attention

This Month's Minh feature: how to appropriately wear your PPE



Stay safe. Stay well. Thank you for all that you do.