


GATOR DOC PERIODICAL

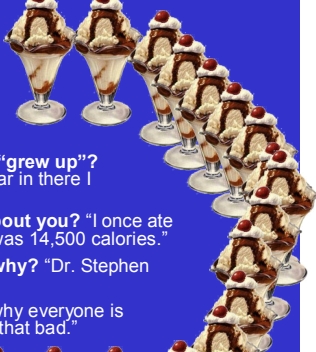
UF Internal Medicine Newsletter

Get to know your March Intern and Resident of the Month!



William King, PGY-1 AKA King of the Bubly

- Where are you from? "Wilmington, NC"
- As a child, what did you want to be when you "grew up"? "A doctor from age 4-7 and from 8-26. For one year in there I wanted to be a pool digger"
- What is something most people don't know about you? "I once ate 25 ice cream sundaes in 7 minutes for charity. It was 14,500 calories."
- Who is your role model (real or fictional) and why? "Dr. Stephen Owen Amann, M.D. No need for explanation."
- Anything else you'd like to say? "I don't know why everyone is complaining about Salad Creations. It's really not that bad."



Kenny Chang, PGY-3

- Where are you from? "Southern California"
- What is your favorite food? "Sushi"
- What is something most people don't know about you? "I have a tattoo :O"
- What is your life motto? "When we have something good it should always be kept."
- Anything else you'd like to say? "You all will be missed!"




Special Congratulations

Congratulations to the following amazing interns to acceptance to our specialized clinical tracks!



John Friary



Vishal Patel


Primary Care Track



Ray Richhart



Varsha Kurup



Ruchira Khosavanna




Andrew Stein

Global Health Track




Aditi Patel



William King



Madeline Smoot



Nicole Gilreath

Clinical Educator Track

QUESTION OF THE MONTH

Topic: Rheumatology

Answer at the bottom of newsletter

A 32yo woman is evaluated for a 15-year history of low back pain. The pain is worse with rest and improves with movement. Family history is notable for 3 paternal uncles with back problems. She takes naproxen twice daily with some relief. On exam, vital signs are normal, joint exam with no warmth, erythema, or swelling. Tenderness is noted over the sacroiliac joints bilaterally with reduction in range of motion of lumbar spine. Laboratory results notable for ESR 27. A plain anteroposterior radiograph of pelvis shows fusion of sacroiliac joints.

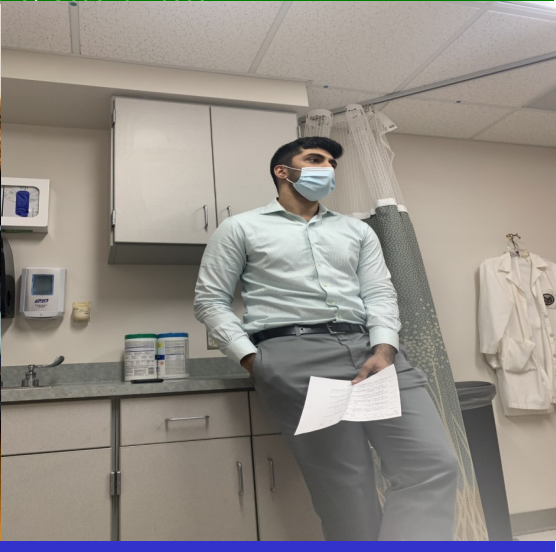Which of the following is the most appropriate diagnostic test to perform next?

- A. ANCA
- B. Anti-cyclic citrullinated peptide antibodies
- C. Antinuclear antibodies
- D. HLA-B27 antigen
- E. No additional testing

UF IM Residency Out and About!



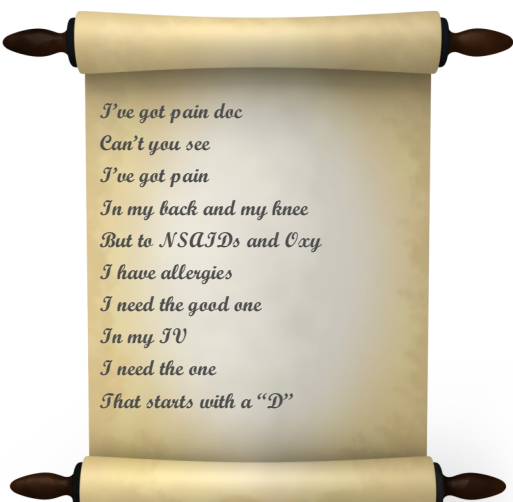
Shands Gold aka Team Chaotic Evil



Walid Khan chilling in clinic



Shands Gold (with sub senior) s/p ER visits



I've got pain doc
Can't you see
I've got pain
In my back and my knee
But to NSAIDs and Oxy
I have allergies
I need the good one
In my IV
I need the one
That starts with a "D"

A poem by William King

Night life guide by Lindsey Woody




Anxious patient? Atarax for you!

MEWS of 4? MD Aware

AMA? Door is that way!



Sepsis Alert? Hit 'em with Vanc/Cefepime



End of shift, another night in the books. Victory!

Question of the Month Answer: E. No additional testing

Want to be featured in the next Gator Doc Periodical? We are looking for contributors and photos! #HarrisKhanSightings will be prioritized. Email Andy Lopez at Andres.Lopez@medicine.ufl.edu!