

GATOR DOC PERIODICAL

UF Internal Medicine Newsletter

PET EDITION!!

Get to know your January Interns and Residents of the Month!



James Caldwell, PGY-1

- Where are you from? "Bastrop, LA"
- As a child, what did you want to be when you "grew up"? "F1 Racing Driver; now I just race in straight lines"
- What is your favorite food? "Nothing better than a good crawfish boil"
- Who is your role model (real or fictional) and why? "Drew Brees. Best quarterback in Saints football history plus he helped rebuild most of our state after Katrina"
- Who is your starter Pokemon? "Depends, overall favorite is Totodile. If I'm putting together a competitive team, then I go with Torchic. Yeah, I was the best Pokemon trainer at my school"



Blake Thompson, PGY-3

- Voted as most handsome and most likely to serve as host for "The Bachelor" in the future; what more do you need to know


Step aside Chris Harrison,
there's a new sheriff in
town



The Adventures of Leuk & Friends




This is Leuk, our resident long-haired Weimaraner! He lives with his loving parents and his stray-cat brother Tom. Momma Lindsey has made it her mission to have Leuk meet every resident dog. Let's see who he's met so far!



Maggie! (Janelis Gonzalez)



Wrigley! (Jeff Budweg), can you guess his favorite team?



Charlotte & Lyla! (Jessica Hundal)



Playdate at The Lindsey Woody Dog Park!



That is one happy pup!

But wait, there's more fantastic pets!!



Opus! (Alexa Collazo)



Bennet & Darcy! (Andy Lopez)



Alice! (MaryKate Wilson)



Scrubs! (Brittney Ginsburg)



Alice! (MaryKate Wilson)

QUESTION OF THE MONTH

Topic: Animal Bites

Answer at the bottom of newsletter

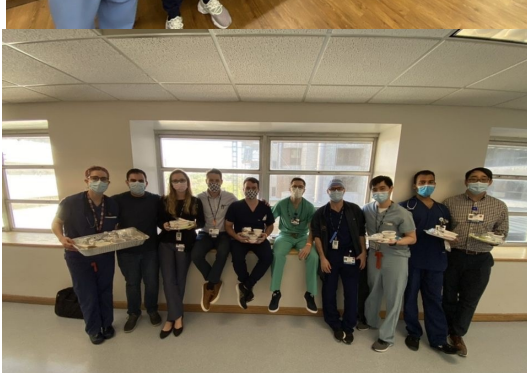A 50-year old woman is evaluated in the ED for fever and tenderness at the site of a cat bite on her right hand 2 days ago. She indicates that she works at an animal shelter. She has a previous history of MRSA skin infection 6 months ago. She is up to date on all vaccinations including rabies and tetanus. On exam, temperature is 38.5C, BP 98/66, HR 110, RR 22. A tender puncture wound is noted on the dorsum of the right hand which is warm, surrounded by significant erythema, with purulent drainage coming from the wound. Plan radiograph of the right hand shows no evidence of gas, foreign body or bony involvement.

In addition to a surgical consultation, which of the following antibiotic regimens is the most appropriate treatment at this time?

- Ampicillin-sulbactam + Vancomycin
- Ceftriaxone + metronidazole
- Ciprofloxacin + aztreonam
- Imipenem
- Vancomycin + clindamycin

Resident Appreciation!

If it wasn't stressed enough, once again remember that you are appreciated! From our program and assistant program directors, to our chief residents and to your fellow residents!



IM Residents Out and About!




Tower Hill celebrates Valentines!



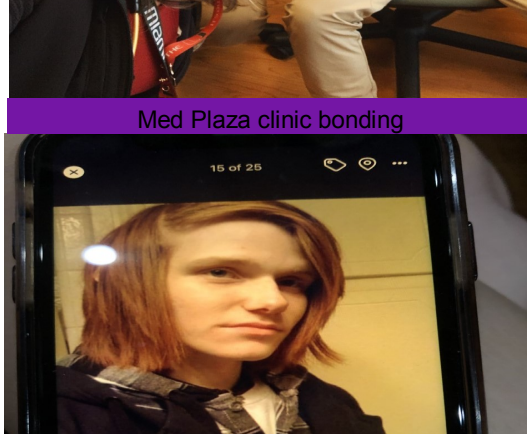
CCU February A




Med Plaza clinic bonding



ED Doppelgängers?!



Dr. Jake Wilson....is that you?? (circa 2009)



Matt Bloom with Scrubs!

Question of the Month Answer: A. Ampicillin-sulbactam + vancomycin

Want to be featured in the next Gator Doc Periodical? We are looking for contributors and photos! #HarrisKhanSightings will be prioritized. Email Andy Lopez at Andres.Lopez@medicine.ufl.edu!